

Letter to the Editor

Liver abnormality may develop cerebral vein thrombosis in COVID-19



ARTICLE INFO

Keywords:

Liver abnormality
CVST
COVID-19

Dear Editor:

We read with great interest the manuscript written by Garaci and colleagues [1] describing venous cerebral thrombosis in COVID-19 patient. Here we describe markedly elevated liver enzymes by SARS-CoV-2 infection that may develop hypercoagulability and CVST.

A 43-year-old previously healthy woman with headache for one day developed a single episode of generalized tonic-clonic seizure with postictal drowsiness. She admitted to the emergency department with loss of consciousness. Her vital signs were stable and oxygen saturation was 95% on room air. She had no focal neurologic signs. Initial brain computed tomography (CT) was suggestive of cerebral venous sinus thrombosis (Fig. 1.C-D), then magnetic resonance imaging (MRI) and magnetic resonance venography (MRV) performed and revealed thrombosis in the superior sagittal sinus, internal cerebral vein, and straight sinus, and also hyperintensities in bilateral thalami (more prominent in the left-side), bilateral basal ganglia, and left temporal lobe in favor of venous infarction (Fig. 1.E-J). Chest CT showed multilobar areas of ground glass opacity (GGO) in peripheral and subpleural areas (Fig. 1.A-B), in agreement with this, reverse transcription polymerase chain reaction (RT-PCR) confirmed positive COVID-19. Laboratory testing revealed WBC count (13.1×10^9 /L, LYM: 17%, PMN: 81%), Hb (11.9 g/dL), Platelet (269×10^9 /L), blood sugar (190 mg/dL), CRP (32 mg/L), ESR (79 mm), ALT (978 U/L), AST (1110 U/L), ALK-P (194 IU/L), Bili-Total (1.1 mg/dL), PT (13 s), PTT (31 s), and LDH (1660 U/L). The cerebrospinal fluid (CSF) analysis showed a traumatic tap with normal parameters and negative culture and gram staining, however RT-PCR for SARS-CoV-2 was unable to be performed. Predisposing factors for thrombophilia were ruled out using standard lab tests. Regarding the elevated liver tests, viral hepatitis markers were negative and liver ultrasound did not exhibit any pa-

thology. She received levetiracetam, hydroxychloroquine, oseltamivir, and ceftriaxone in addition to low molecular weight heparin as an anticoagulant. After 8 days of hospitalization, her clinical status showed improvement and on day 15 she discharged home with good general condition while she was conscious and her lab tests including liver function became near normal.

Markedly elevated liver tests in our case were met abnormal liver function tests in COVID-19 patients in previous reports that have been linked to a higher risk of disease severity [2]. Furthermore, before developing respiratory symptoms, infection of COVID-19 can be presented as acute hepatitis [3]. Elevation of hepatic enzymes were associated with higher incidence of venous thromboembolism [4] and although it is uncommon acute viral hepatitis has been related to thrombotic events [5].

It has been shown that there is a high thrombotic risk in severe COVID-19 [6]. COVID-19 might lead to cerebrovascular events through different mechanisms of action, including coagulopathy [7]. Even though this patient had a history of oral contraceptive consumption, it does not exclude the possibility that her CVST attack could be precipitated by her infection. In this context, Cavalcanti et al. reported CVT associated with COVID-19 [8].

We speculate that markedly elevated liver enzymes in this patient with COVID-19 led to hypercoagulability and developed CVST. This evidence indicates the neurological manifestations in COVID-19 and highlights the increase in liver enzymes as a possible precipitating factor for CVST in COVID-19, which may provide better strategy for the prevention and treatment of the SARS-CoV-2 targeting central nervous system. We also suggest that patients with acute liver abnormality to be isolated and undergo testing for COVID-19.

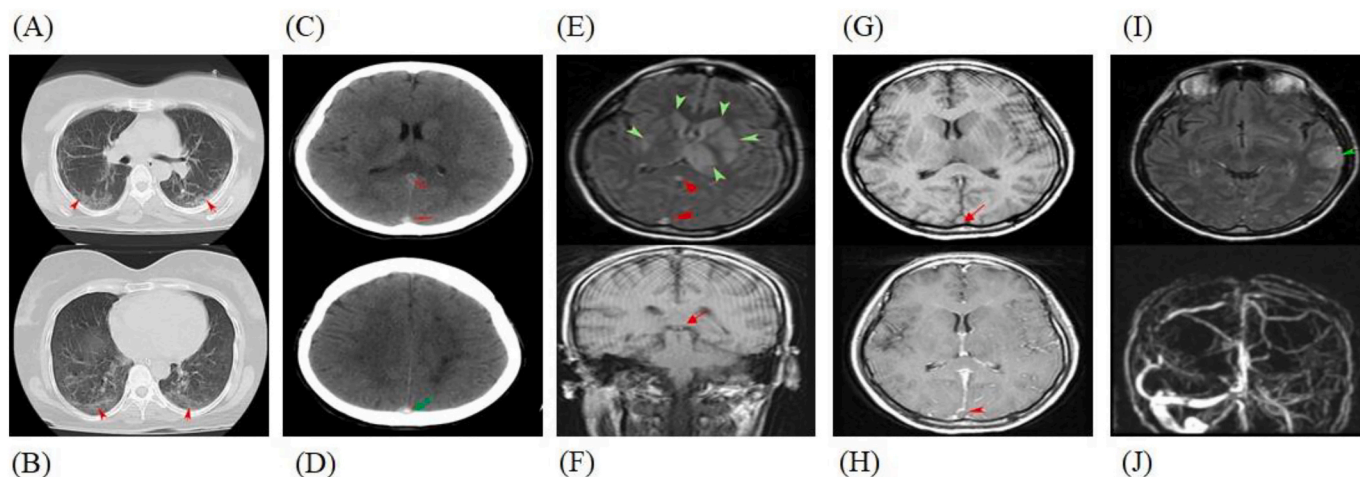


Fig. 1. A-B, non-contrast lung CT scan at two cross-sections exhibits multilobar areas of ground-glass opacity (GGO) in the peripheral and subpleural band (red arrowhead) in favor of COVID-19. C-D, non-contrast brain CT scan demonstrates increased density within straight sinus (red arrowhead) and superior sagittal sinus (green arrow). E, axial FLAIR image shows hyperintensity involving the bilateral thalami (most prominent in the left-side) and bilateral basal ganglia (green arrowhead). Findings were compatible with thrombosis of superior sagittal sinus, straight sinus, both internal cerebral veins and left transverse sinus (red arrowhead). F, coronal T1 weighted image shows hyperintensity at both internal cerebral veins in favor of thrombosis (red arrow). G-H, axial T1 weighted images show lack of signal void at superior sagittal sinus and after GAD injection at the same image, the thrombosis is more visible (red arrowhead). I, hyperintensity at left temporal lobe in favor of venous infarction (green arrowhead), (J) MR venography demonstrates the absence of normal flow-related signal within the deep cerebral veins. (For interpretation of the references to colour in this figure legend, the reader is referred to the web version of this article.)

Disclosure statement

The authors declare no competing interests.

References

- [1] F. Garaci, F. Di Giuliano, E. Picchi, V. Da Ros, R. Floris, Venous cerebral thrombosis in COVID-19 patient, *J. Neurol. Sci.* 414 (2020 Jul 15) 116871, <https://doi.org/10.1016/j.jns.2020.116871> Epub 2020 May.
- [2] Q. Cai, D. Huang, H. Yu, et al., COVID-19: Abnormal liver function tests, *J. Hepatol.* 73 (3) (2020) 566–574, <https://doi.org/10.1016/j.jhep.2020.04.006>.
- [3] P. Wander, M. Epstein, D. Bernstein, COVID-19 presenting as acute hepatitis, *Am. J. Gastroenterol.* 115 (6) (2020) 941–942, <https://doi.org/10.14309/ajg.0000000000000660>.
- [4] A.R. Folsom, P.L. Lutsey, N.S. Roetker, et al., Elevated hepatic enzymes and incidence of venous thromboembolism: a prospective study, *Ann. Epidemiol.* 24 (11) (2014) 817–821. e2, <https://doi.org/10.1016/j.annepidem.2014.08.004>.
- [5] L. Galli, V.E. Gerdes, L. Guasti, A. Squizzato, Thrombosis associated with viral hepatitis, *Journal of Clinical and Translational Hepatology* 2 (4) (2014 Dec) 234–239, <https://doi.org/10.14218/jcth.2014.00031>.
- [6] C. Lodigiani, G. Iapichino, L. Carenzo, et al., Venous and arterial thromboembolic complications in COVID-19 patients admitted to an academic hospital in Milan, Italy, *Thromb. Res.* 191 (2020) 9–14, <https://doi.org/10.1016/j.thromres.2020.04.024>.
- [7] D.C. Hess, W. Eldahshan, E. Rutkowski, COVID-19-related stroke, *Transl. Stroke Res.*

11 (3) (2020 Jun) 322–325, <https://doi.org/10.1007/s12975-020-00818-9> (Epub 2020 May 7. PMID: 32378030; PMCID: PMC7202903).

- [8] D.D. Cavalcanti, E. Raz, M. Shapiro, S. Dehkharghani, S. Yaghi, K. Lillemo, E. Nossek, J. Torres, R. Jain, H. Riina, A. Radmanesh, P.K. Nelson, Cerebral venous thrombosis associated with COVID-19, *Am. J. Neuroradiol.* 41 (8) (2020) 1370–1376, <https://doi.org/10.3174/ajnr.A6644>.

S. Aghayari Sheikh Neshin^a, S. Basirjafari^b, A. Saberi^a, B. Shahhosseini^c, M. Zarei^{d,*}

^a Department of Neurology, Poursina Hospital, Guilan University of Medical Sciences, Rasht, Iran

^b Department of Radiology, Hashemi Rafsanjani Hospital, North Khorasan University of Medical Sciences, Shirvan, Iran

^c Department of Pediatrics, Imam Khomeini Hospital, North Khorasan University of Medical Sciences, Shirvan, Iran

^d Mitochondrial and Epigenomic Medicine, and Department of Pathology and Laboratory Medicine, Children's Hospital of Philadelphia and Perelman School of Medicine, University of Pennsylvania, Philadelphia, PA 19104, USA.

E-mail address: zareim@email.chop.edu (M. Zarei).

* Corresponding author at: Department of Pathology and Laboratory Medicine, Children's Hospital of Philadelphia and Perelman School of Medicine, University of Pennsylvania, Philadelphia, PA, 19104, USA.