



# Neonatal SARS-CoV-2 Infection and Congenital Myocarditis: A Case Report and Literature Review

Reza Amiraskari<sup>1</sup>, Elaheh Sayarifard<sup>1</sup>, Hamed Kharrazi<sup>1</sup>, Neda Naserfar<sup>1</sup> and Azadeh Sayarifard<sup>2,\*</sup>

<sup>1</sup>Pirooz Hospital, Guilan University of Medical Sciences, Lahijan, Iran

<sup>2</sup>Growth and Development Research Center, Tehran University of Medical Sciences, Tehran, Iran

\*Corresponding author: Associate Professor, Community and Preventive Medicine Specialist, Growth and Development Research Center, Tehran University of Medical Sciences, Tehran, Iran. Email: drsayarifard@gmail.com

Received 2020 April 08; Revised 2020 May 17; Accepted 2020 June 04.

## Abstract

**Introduction:** With the outbreak of coronavirus 2019 (SARS-COV-2), the prevention and control of SARS-COV-2 infection in pregnant women and the potential risk of vertical transmission has become a major concern.

**Case Presentation:** We report the case of a newborn in Iran with the manifestations of myocarditis at birth. The diagnosis of SARS-COV-2 infection was confirmed for the mother and the neonate by real-time reverse transcription polymerase chain reaction (rRT-PCR) using a pharyngeal specimen.

**Conclusions:** Based on our literature review, there is still insufficient evidence to determine the effect of SARS-COV-2 infection on the fetus. Given the possibility of cardiac injury in SARS-COV-2 disease and manifestation of congenital myocarditis in our case, maternal vertical transmission of SARS-COV-2 could be considered.

**Keywords:** SARS-CoV-2 Infection, Neonatal, Myocarditis, Congenital

## 1. Introduction

In December 2019, an outbreak of coronavirus 2019 (SARS-COV-2) was reported in Wuhan, a city in China, which spread to other cities in China and to other countries in the world (1). The outbreak of SARS-COV-2 has been declared a global public health emergency by the World Health Organization (WHO) (2). The virus is transmitted through respiratory droplets or contact, and human-to-human transmission has been reported (3).

Angiotensin-converting enzyme 2 (ACE2) is indicated as a receptor for SARS-CoV-2, which is expressed in human placenta (4). Thus, with the outbreak of SARS-COV-2, the prevention and control of the infection in pregnant women and the potential risk of vertical transmission have become a major concern (5-7).

There is still insufficient information to determine the effect of SARS-COV-2 infection on the fetus. Whether SARS-COV-2 has a maternal vertical transmission is still unclear (8). However, some studies have provided information on the clinical features, pregnancy outcomes, and potential of vertical transmission of SARS-COV-2 infection in pregnant women (5, 7, 9), but more evidence is needed to develop effective preventive strategies (8, 10).

Following the crisis of SARS-COV-2 disease in different

parts of the world, this outbreak in Iran was officially approved in February 2020. Guilan province is one of the 31 provinces of Iran and was one of the first provinces with SARS-COV-2 cases. Since studies on neonates with SARS-COV-2 are limited (11), our aim is to introduce a case of neonatal SARS-COV-2 infection in Guilan province of Iran to share our experience with those involved in the care and management of this disease. In addition, we performed a short review of the literature related to this case.

## 2. Case Presentation

On March 11, 2020, a 36-week pregnant woman visited Pirooz Hospital, a general hospital in Lahijan city of Guilan province, due to fever, cough, and respiratory distress.

The fever and cough had begun a week ago, but the patient had only taken acetaminophen tablets to control fever. She was gravid 1 and had no specific diseases. She had had exposure to a suspected SARS-COV-2 case in her family.

On admission, her vital signs were as follows: body temperature 38.5°C, respiratory rate 27 breaths per minute, pulse rate 125 per minute, and blood pressure 90/60 mmHg. The patient's O<sub>2</sub> saturation (SpO<sub>2</sub>) was 60% to 70%. Fetal heart rate (FHR) was 80 - 100 bpm, and fetal heart

monitoring showed fetal distress. Ultrasound examination showed oligohydramnios, but the exact time of rupture of membranes was not known, and the patient mentioned a sense of discharge one day before admission.

Possible SARS-COV-2 pneumonia was diagnosed based on the patient's clinical presentations and history of exposure. The treatment plan was given based on the hospital's protocol for SARS-COV-2. Meropenem (1g stat, then 1g every 8 hours intravenously), vancomycin (1gr stat, then 1g every 12 hours intravenously), hydroxychloroquine (200 mg stat, oral), kaletra (400 mg every 12 hours, oral), and Tamiflu (75 mg every 12 hours, oral) were prescribed.

An emergency cesarean section was performed for the patient because of fetal distress. Meconium staining was shown intraoperatively. A female neonate with weight 2900 g, height 48 cm, and head circumference 33 cm was delivered. Apgar scores at 1 and 5 minutes after birth were 7 and 8, and the neonate was transferred to the neonatal intensive care unit (NICU) because of respiratory distress, and the mother transferred to the intensive care unit (ICU).

Immediately after birth, the newborn was transferred to the NICU with a sterile incubator and placed in an isolated room. There was not any contact between the mother and the infant. The treatment team followed individual protective conditions and infection control principles during patient management.

The result of a pharyngeal swab sample for real-time reverse transcription polymerase chain reaction (rRT-PCR) showed positive SARS-COV-2 for the mother. However, samples for the SARS-COV-2 test were not taken from the amniotic fluid, cord blood, and placenta. Unfortunately, the mother died after 4 days of hospitalization in the ICU.

On arrival to NICU, the newborn had severe respiratory distress with respiratory rate 70 per minute, intercostal and subcostal retractions, and SpO<sub>2</sub> 82%, so she was intubated. The neonate was connected to a ventilator for respiratory support, and surfactant (2.5 cc/kg) was injected intratracheally, then SpO<sub>2</sub> reached 95% with PIP = 30 cmH<sub>2</sub>O, ventilator rate = 60 and PEEP = 5 cmH<sub>2</sub>O. A second dose of surfactant (1.25 cc/kg) was injected intratracheally 12 hours later due to high FiO<sub>2</sub> requirement, and then PIP and FiO<sub>2</sub> were gradually diminished. The neonate was extubated 24 hours after birth and was given respiratory support with nasal continuous positive airway pressure (C-PAP).

The neonate was echoed at the first 12 hours of birth. The first echocardiography showed ejection fraction (EF) 40%, mild pulmonary hypertension (PH), and left and right ventricular dilation.

Milrinone with the loading dose of 75 mcg/kg was infused over 60 minutes with the maintenance infusion of 0.5 mcg/kg per minute, immediately after a loading dose of 1 mg/kg furosemide was given every 12 hours and 1 mg/kg spironolactone was administered daily.

On the third day of birth, a second echocardiography showed EF: 35%, PH: 37 mmHg and mild mitral regurgitation (MR), and 10 mcg/kg/min dobutamine and 1 gr/kg intravenous immunoglobulin (IVIG) were given.

On the fourth day of birth, pharyngeal and nasal mucosa specimen were collected for SARS-COV-2 test, which was positive for the neonate.

On the fifth day of birth, the third echocardiography showed EF: 55% and trivial MR. Gradually, the cardiac medications were reduced, and she was separated from nasal C-PAP and received oxygen through the hood, and formula feeding was begun. After 10 days, all the medications were discontinued, and the IV line was withdrawn. Finally, the baby was discharged on March 26, 2020, with improvement in heart and respiratory status and in good general condition.

The neonate laboratory test results are shown in [Table 1](#).

**Table 1.** Laboratory Findings of Neonate

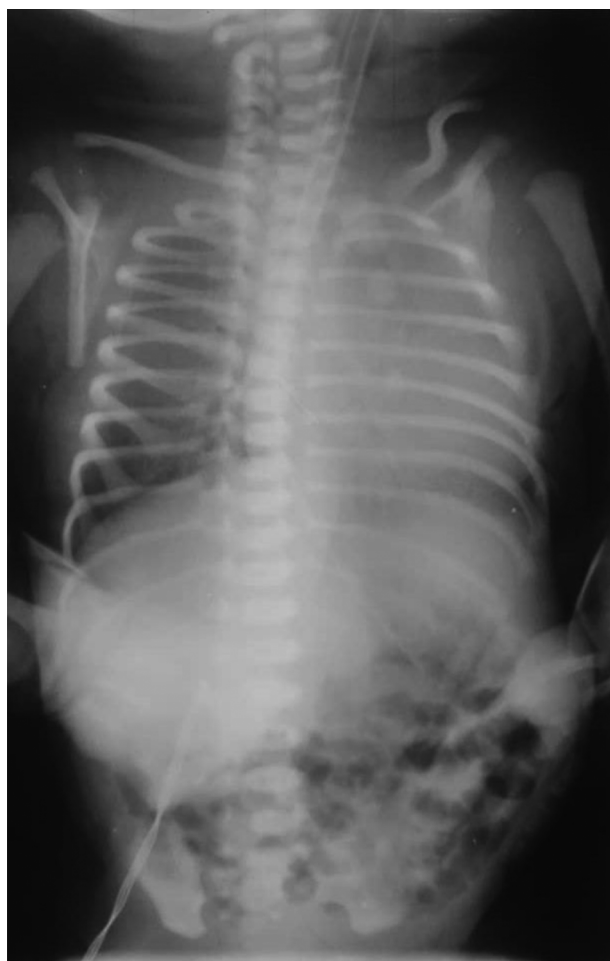Test	In Patient	Normal Range
WBC ( $\times 10^9/L$ )	13.2	9 - 30
Hb (g/L)	12.6	12 - 16
PLT ( $\times 10^9/L$ )	218	150 - 350
CRP(mg/L)	0.1	0 - 0.8
Ca (mg/dL)	8.2	8 - 11
Na (mmol/L)	137	136 - 145
K(mmol/L)	3.8	3.5 - 5
AST (U/L)	36	0 - 35
ALT (U/L)	46	0 - 35
Urea (mg/dL)	19	10 - 40
Cr (mg/dL)	1.1	0.7 - 1.3
CPK (U/L)	1666	195 - 700
LDH (U/L)	2032	160 - 450

Troponin was negative. Blood gas analysis of the neonate showed (first day of birth): pH: 7.08 (normal range: 7.30 - 7.35), PCO<sub>2</sub> (mmHg): 50 (normal range: 35 - 45), HCO<sub>3</sub> (mEq/L): 9.5 (normal range: 22 - 25), BE/BD (mmol/L): -1.7 (normal range:  $\pm 3$ ), SpO<sub>2</sub>: 82%, blood group: O<sup>+</sup>, and blood culture: no growth.

The first chest X-ray (CXR) after intubation: Except mild hyperinflation and cardiomegaly, no other significant finding was visible ([Figure 1](#)).

The second CXR, four hours after injection of the second dose of surfactant, showed mild hyperinflation that was decreased in comparison to previous CXR ([Figure 2](#)).

The third CXR, on the fifth day of birth: the lung tissue, had a normal pattern ([Figure 3](#)).

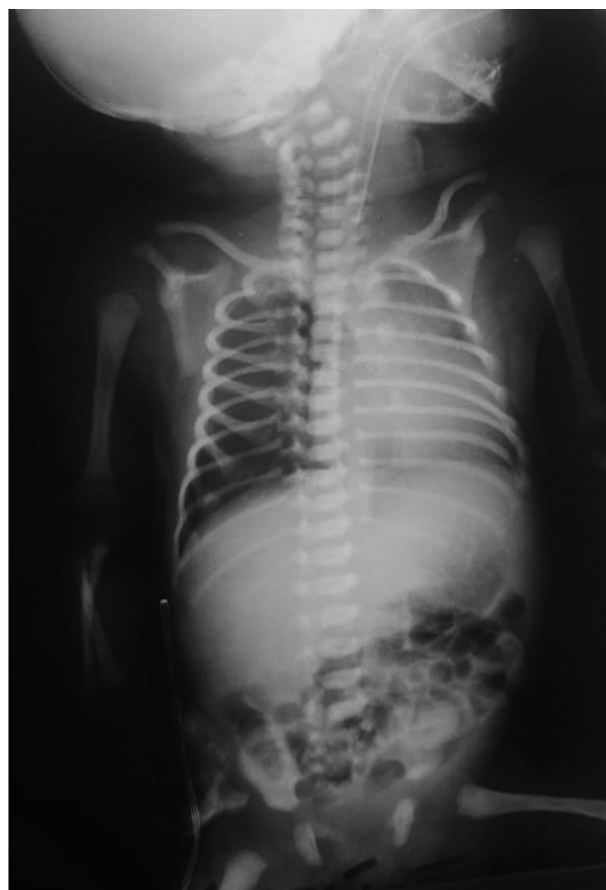

**Figure 1.** Except mild hyperinflation and cardiomegaly no other significant findings was visible

### 3. Discussion

We reported the case of a newborn in Iran with the diagnosis of SARS-COV-2 based on clinical symptoms, mother's history, and positive rRT-PCR test for the mother and the neonate. The clinical manifestations of the mother were severe, and there was fatal distress that led to the preterm labor and emergency cesarean section. SARS-COV-2 infection in the mother could have caused hypoxemia and increased risk of birth asphyxia and premature birth (5). However, changes in the fetal heart rate pattern may also be a sign of severe maternal respiratory distress (12). A rapid review reported preterm delivery occurred in 47% of pregnant women with SARS-COV-2, which can put considerable pressure on maternal and neonatal care services (13).

The neonate's test for SARS-COV-2 was positive on the

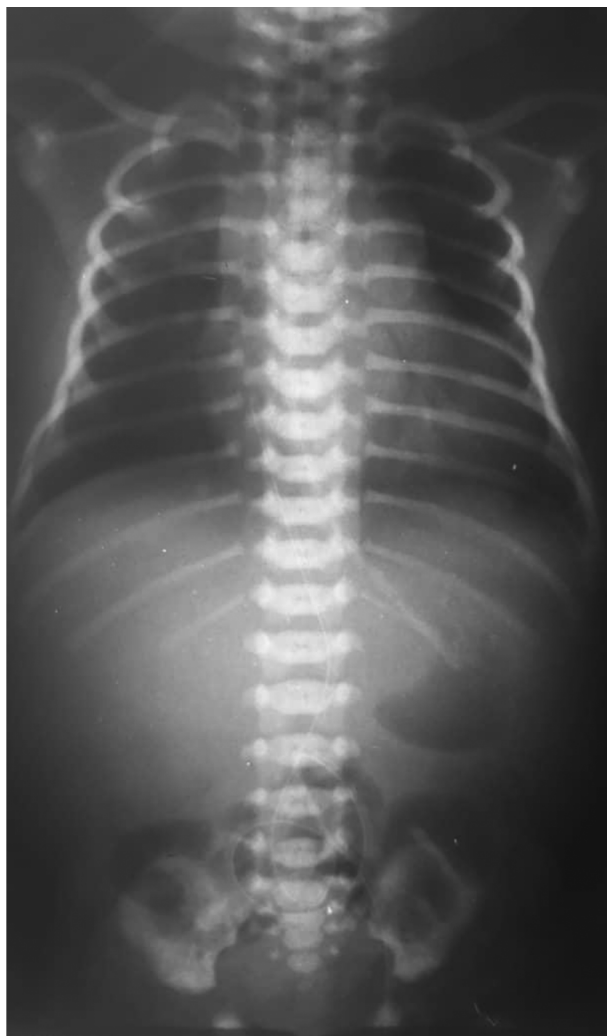


**Figure 2.** The second chest X-ray of neonate at first birth of day after injection of second dose of surfactant: mild hyperinflation that was decreased in comparison to previous CXR

fourth day of birth. Because of our resource limitation, SARS-COV-2 test for neonates is performed if the mother's test is positive. Therefore, immediately after the positive report of the mother's test, the neonate was tested for SARS-COV-2.

Different transmission routes might be considered for neonatal infection, including: (1) vertical transmission from the mother to the fetus during pregnancy; (2) contact between maternal blood and body fluid with the fetus during a cesarean; and (3) other contact transmission of newborns in the hospital.

In our case, the mother had some symptoms related to SARS-COV-2 from approximately one week before admission and an exposure to a suspected SARS-COV-2 case in her family. Although due to the limitations of diagnostic testing for SARS-COV-2 in the hospital, diagnostic testing of amniotic fluid, cord blood, and the placenta was not performed, but intrauterine vertical transmission could not



**Figure 3.** The third chest x-ray of neonate at fifth day of birth: the lung tissue had normal pattern

be ruled out for the presented case. We tried to meet the isolation strategy for the baby, but it was not possible to rule out the other contact transmission.

In the first case report of a neonate with pharyngeal swabs tested positive by rRT-PCR assay 36 hours after birth, introduced by Wang et al. in Wuhan, China, the results of nucleic acid testing of the placenta and cord blood were negative, but the authors stated that the possibility of vertical intrauterine transmission of SARS-CoV-2 could not be ruled out in that case (7).

Zhu et al. also reported the clinical manifestations and health outcomes of nine pregnant mothers with SARS-CoV-2 and their neonates in China. Early symptoms of neonates included fever, respiratory distress, gastro-intestinal symp-

toms, vomiting, and increased heart rate. The pharyngeal swab sample of the neonates was negative for 2019-nCoV one to nine days after birth. However, false negative results should be considered, and the authors concluded perinatal 2019-nCoV infection could cause problems such as fetal distress, preterm labor, respiratory distress, and even death in neonates. Another result in that study was that early intravenous injection of immunoglobulin may reduce neonatal morbidity and mortality (5). We also used IVIG for the baby, and we believe it was helpful for the patient's improvement, but further studies are needed for this issue.

Chen also examined the clinical features and potential of intrauterine vertical transmission of SARS-CoV-2 infection in nine pregnant women in China. The study reported no evidence of intrauterine infection caused by vertical transmission of SARS-CoV-2 in late pregnancy. Just one neonate had a mild increase in myocardial enzymes on the day of birth without any clinical symptoms (9).

Li et al. in a study assessed 16 confirmed SARS-CoV-2 pregnant women and 18 suspected cases and reported no SARS-CoV-2 infection in their neonates. Also, severe complications of SARS-CoV-2 pneumonia were not seen in any of the mothers and neonates (14).

Schwartz reported no evidence of intrauterine transmission in pregnant women with SARS-CoV-2 (15). In Fan et al.'s study, also SARS-CoV-2 was not detected in the two studied neonates (16).

Dong reported a newborn with elevated SARS-CoV-2 IgM antibodies (probably due to infection in utero) with a COVID-19 infected mother. However the increased IgM suggested the infection in utero, the results from repeated RT-PCR tests in neonate was negative and was difficult to explain for authors (17).

Zeng reported 33 neonates born to mothers with SARS-CoV-2 that nasopharyngeal and anal swabs were positive for SARS-CoV-2 on days 2 and 4 of life in 3 neonates (18).

Yu et al. presented seven cases of COVID-19 in late pregnancy that 4 neonates without any symptoms were not tested and 3 neonates remained for observation and were tested for SARS-CoV-2. Test of one neonate was positive at 36 hours after birth (19).

A summary of the data derived from the literature review related to neonatal cases of mothers with SARS-CoV-2 infection is presented in Table 2.

Overall some of the previous studies evaluated the presence of SARS-CoV-2 in the amniotic fluid, placenta tissues, umbilical cord blood, newborn's nasopharyngeal. Some studies reported positive rRT-PCR and some of them reported negative rRT-PCR however false negative result for rRT-PCR should be considered because of viral load or insufficient collecting of samples (20).

Chinese consensus on the prevention and control of



**Table 2.** The Summary of Data Related to Neonatal Cases of Mothers with SARS-COV-2 Infection

Author	Number of Neonatal Cases	Specimens for SARS-COV-2 Tests	Clinical Findings	Chest X-Ray
Wong et al. (7)	1	Cord blood, placenta and neonatal throat	Vomiting once after feeding formula	Lung texture with no abnormalities in heart and palate
Zhu et al. (5)	10	Neonatal throat	Fever, shortness of breath, rapid heart rate, vomiting feeding intolerance, bloating, refusing milk, and gastric bleeding	Infections, neonatal respiratory distress syndrome and pneumothorax
Chen et al. (9)	9	Amniotic fluid, cord blood and neonatal throat	No events of neonatal asphyxia	-
Li et al. (14)	17	Neonatal throat	No events of severe neonatal asphyxia	-
Fan et al. (16)	2	Amniotic fluid, placenta tissues, umbilical cord blood and newborn's Nasopharyngeal	Fever and abdominal distension	Haziness in lung field without patchy consolidation
Dong et al. (17)	1	Nasopharyngeal	No symptom	-
Zeng et al. (18)	33	Nasopharyngeal and anal	Asphyxia, fever, shortness of breath, feeding intolerance, cyanosis	Radiographic findings were nonspecific
Yu et al. (19)	7	Neonatal throat	mild shortness of breath symptoms	mild pulmonary infection

SARS-COV-2 during the prenatal and neonatal period recommended that delayed cord closure be avoided. Contact between mother and baby is not recommended. Physicians and nurses who care for mothers and neonates suspected of SARS-COV-2 should have appropriate protective equipment (21).

In some studies, it is mentioned that SARS-COV-2 disease can cause acute cardiac injury (3, 22). What makes the presented case different from the newborns reported in other studies was the manifestations of congenital myocarditis, which, according to the reports of SARS-COV-2 cases with myocarditis, predispose them to fetal involvement during pregnancy. However, a negative troponin does not exclude the diagnosis of myocarditis (23, 24). In our case, progressive manifestations in the echocardiogram included elevated pulmonary pressure and decreased EF despite relieving respiratory distress and extubation, and response to IVIG and Millerine was in favor of myocarditis.

In Wang et al.'s study on a cohort of 138 patients with SARS-COV-2 hospitalized in China, cardiac injury (increased troponin, abnormality in electrocardiogram, or echocardiography) was reported in 7.2% of the patients (25). The case presented by Zeng et al. was a 63-year-old man with SARS-COV-2 in China who had increased troponin and myocardial dyskinesia with decreased left ventricular EF on echocardiography who was treated with a diagnosis of fulminant myocarditis (26). Hu et al. also presented the case of a 37-year-old man diagnosed with coronavirus fulminant myocarditis and suggested that early treatment with immunoglobulin therapy, glucocorticoid, and anti-

inflammatory therapy was important in the management of this case (27). However, mechanisms that may explain cardiac involvement in SARS-COV-2 are currently unclear and need more investigations (28). Guo et al. reported inflammation may be a potential mechanism for myocardial injury for patients with SARS-COV-2 (29).

Since all aspects of SARS-COV-2 infection have not yet been identified, the consequences can be complex and difficult to control in the mother and neonate if the health services are not prepared. Therefore, in addition to health education and prevention, careful evaluations, and appropriate interventions through a multi-disciplinary team (12) for the care of pregnant women and neonates based on evidence are essential (30).

We believe that our case report can be helpful for understanding the clinical and paraclinical characteristics of neonates with SARS-COV-2, especially with myocarditis. However, further studies are needed to prove the possibility of intrauterine vertical transmission of SARS-COV-2 infection from the mother to the fetus and to determine the mechanism of cardiac injury in SARS-COV-2 infection.

### 3.1. Conclusions

The presented case was a neonate with confirmed SARS-COV-2 infection that had respiratory distress and manifestations of myocarditis at birth and was improved with care and treatment. Given the possibility of cardiac injury in SARS-COV-2 disease and manifestation of congenital myocarditis in our case, maternal vertical transmission of SARS-COV-2 could be considered.

## Acknowledgments

We would like to thank all staff of ICU, NICU and the treatment team at Pirooz Hospital. All ethical considerations observed in this study.

## Footnotes

**Authors' Contribution:** Author Contributions: Study concept and design: Reza Amiraskari, Elaheh Sayarifard, and Azadeh Sayarifard; analysis and interpretation of data: Reza Amiraskari, Hamed Kharrazi, Elaheh Sayarifard, and Neda Naserfar; drafting of the manuscript: Azadeh Sayarifard; critical revision of the manuscript for important intellectual content: Reza Amiraskari, Elaheh Sayarifard, Hamed Kharrazi, Neda Naserfar, and Azadeh Sayarifard.

**Conflict of Interests:** All authors have no conflict of interests.

**Funding/Support:** The authors of this study did not receive any Funding.

**Patient Consent:** Informed consent has been obtained from the patients' family to share the details of case.

## References

- Zhu N, Zhang D, Wang W, Li X, Yang B, Song J, et al. A Novel Coronavirus from Patients with Pneumonia in China, 2019. *N Engl J Med*. 2020;**382**(8):727-33. doi: [10.1056/NEJMoa2001017](https://doi.org/10.1056/NEJMoa2001017). [PubMed: [31978945](https://pubmed.ncbi.nlm.nih.gov/31978945/)]. [PubMed Central: [PMC7092803](https://pubmed.ncbi.nlm.nih.gov/PMC7092803/)].
- Stower H. Lack of maternal-fetal SARS-CoV-2 transmission. *Nat Med*. 2020;**26**(3):312. doi: [10.1038/s41591-020-0810-y](https://doi.org/10.1038/s41591-020-0810-y). [PubMed: [32161408](https://pubmed.ncbi.nlm.nih.gov/32161408/)]. [PubMed Central: [PMC7096028](https://pubmed.ncbi.nlm.nih.gov/PMC7096028/)].
- Huang C, Wang Y, Li X, Ren L, Zhao J, Hu Y, et al. Clinical features of patients infected with 2019 novel coronavirus in Wuhan, China. *Lancet*. 2020;**395**(10223):497-506. doi: [10.1016/S0140-6736\(20\)30183-5](https://doi.org/10.1016/S0140-6736(20)30183-5). [PubMed: [31986264](https://pubmed.ncbi.nlm.nih.gov/31986264/)]. [PubMed Central: [PMC7159299](https://pubmed.ncbi.nlm.nih.gov/PMC7159299/)].
- Wang C, Zhou YH, Yang HX, Poon LC. Intrauterine vertical transmission of SARS-CoV-2: what we know so far. *Ultrasound Obstet Gynecol*. 2020;**55**(6):724-5. doi: [10.1002/uog.22045](https://doi.org/10.1002/uog.22045). [PubMed: [32266753](https://pubmed.ncbi.nlm.nih.gov/32266753/)]. [PubMed Central: [PMC7262402](https://pubmed.ncbi.nlm.nih.gov/PMC7262402/)].
- Zhu H, Wang L, Fang C, Peng S, Zhang L, Chang G, et al. Clinical analysis of 10 neonates born to mothers with 2019-nCoV pneumonia. *Transl Pediatr*. 2020;**9**(1):51-60. doi: [10.21037/tp.2020.02.06](https://doi.org/10.21037/tp.2020.02.06). [PubMed: [32154135](https://pubmed.ncbi.nlm.nih.gov/32154135/)]. [PubMed Central: [PMC7036645](https://pubmed.ncbi.nlm.nih.gov/PMC7036645/)].
- Schmid MB, Fontijn J, Ochsenbein-Kolble N, Berger C, Bassler D. COVID-19 in pregnant women. *Lancet Infect Dis*. 2020;**20**(6):653. doi: [10.1016/S1473-3099\(20\)30175-4](https://doi.org/10.1016/S1473-3099(20)30175-4). [PubMed: [32197098](https://pubmed.ncbi.nlm.nih.gov/32197098/)]. [PubMed Central: [PMC7270341](https://pubmed.ncbi.nlm.nih.gov/PMC7270341/)].
- Wang S, Guo L, Chen L, Liu W, Cao Y, Zhang J, et al. A case report of neonatal COVID-19 infection in China. *Clin Infect Dis*. 2020. doi: [10.1093/cid/ciaa225](https://doi.org/10.1093/cid/ciaa225). [PubMed: [32161941](https://pubmed.ncbi.nlm.nih.gov/32161941/)]. [PubMed Central: [PMC7108144](https://pubmed.ncbi.nlm.nih.gov/PMC7108144/)].
- Qiao J. What are the risks of COVID-19 infection in pregnant women? *Lancet*. 2020;**395**(10226):760-2. doi: [10.1016/S0140-6736\(20\)30365-2](https://doi.org/10.1016/S0140-6736(20)30365-2). [PubMed: [32151334](https://pubmed.ncbi.nlm.nih.gov/32151334/)]. [PubMed Central: [PMC7158939](https://pubmed.ncbi.nlm.nih.gov/PMC7158939/)].
- Chen H, Guo J, Wang C, Luo F, Xu X, Zhang W, et al. Clinical characteristics and intrauterine vertical transmission potential of COVID-19 infection in nine pregnant women: a retrospective review of medical records. *The Lancet*. 2020;**395**(10226):809-15. doi: [10.1016/S0140-6736\(20\)30360-3](https://doi.org/10.1016/S0140-6736(20)30360-3).
- Lu Q, Shi Y. Coronavirus disease (COVID-19) and neonate: What neonatologist need to know. *J Med Virol*. 2020. doi: [10.1002/jmv.25740](https://doi.org/10.1002/jmv.25740). [PubMed: [32115733](https://pubmed.ncbi.nlm.nih.gov/32115733/)]. [PubMed Central: [PMC7228398](https://pubmed.ncbi.nlm.nih.gov/PMC7228398/)].
- Mullins E, Evans D, Viner R, O'Brien P, Morris E. Coronavirus in pregnancy and delivery: Rapid review and expert consensus. *medRxiv*. 2020. doi: [10.1101/2020.03.06.20032144](https://doi.org/10.1101/2020.03.06.20032144).
- Rasmussen SA, Smulian JC, Lednický JA, Wen TS, Jamieson DJ. Coronavirus Disease 2019 (COVID-19) and pregnancy: what obstetricians need to know. *Am J Obstet Gynecol*. 2020;**222**(5):415-26. doi: [10.1016/j.ajog.2020.02.017](https://doi.org/10.1016/j.ajog.2020.02.017). [PubMed: [32105680](https://pubmed.ncbi.nlm.nih.gov/32105680/)]. [PubMed Central: [PMC7093856](https://pubmed.ncbi.nlm.nih.gov/PMC7093856/)].
- Mullins E, Evans D, Viner RM, O'Brien P, Morris E. Coronavirus in pregnancy and delivery: rapid review. *Ultrasound Obstet Gynecol*. 2020;**55**(5):586-92. doi: [10.1002/uog.22014](https://doi.org/10.1002/uog.22014). [PubMed: [32180292](https://pubmed.ncbi.nlm.nih.gov/32180292/)].
- Li N, Han L, Peng M, Lv Y, Ouyang Y, Liu K, et al. Maternal and neonatal outcomes of pregnant women with COVID-19 pneumonia: a case-control study. *Clin Infect Dis*. 2020. doi: [10.1093/cid/ciaa352](https://doi.org/10.1093/cid/ciaa352). [PubMed: [32249918](https://pubmed.ncbi.nlm.nih.gov/32249918/)]. [PubMed Central: [PMC7184430](https://pubmed.ncbi.nlm.nih.gov/PMC7184430/)].
- Schwartz DA. An Analysis of 38 Pregnant Women with COVID-19, Their Newborn Infants, and Maternal-Fetal Transmission of SARS-CoV-2: Maternal Coronavirus Infections and Pregnancy Outcomes. *Arch Pathol Lab Med*. 2020. doi: [10.5858/arpa.2020-0901-SA](https://doi.org/10.5858/arpa.2020-0901-SA). [PubMed: [32180426](https://pubmed.ncbi.nlm.nih.gov/32180426/)].
- Fan C, Lei D, Fang C, Li C, Wang M, Liu Y, et al. Perinatal Transmission of COVID-19 Associated SARS-CoV-2: Should We Worry? *Clin Infect Dis*. 2020. doi: [10.1093/cid/ciaa226](https://doi.org/10.1093/cid/ciaa226). [PubMed: [32182347](https://pubmed.ncbi.nlm.nih.gov/32182347/)]. [PubMed Central: [PMC7184438](https://pubmed.ncbi.nlm.nih.gov/PMC7184438/)].
- Dong L, Tian J, He S, Zhu C, Wang J, Liu C, et al. Possible Vertical Transmission of SARS-CoV-2 From an Infected Mother to Her Newborn. *JAMA*. 2020. doi: [10.1001/jama.2020.4621](https://doi.org/10.1001/jama.2020.4621). [PubMed: [32215581](https://pubmed.ncbi.nlm.nih.gov/32215581/)]. [PubMed Central: [PMC7099527](https://pubmed.ncbi.nlm.nih.gov/PMC7099527/)].
- Zeng L, Xia S, Yuan W, Yan K, Xiao F, Shao J, et al. Neonatal Early-Onset Infection With SARS-CoV-2 in 33 Neonates Born to Mothers With COVID-19 in Wuhan, China. *JAMA Pediatr*. 2020. doi: [10.1001/jamapediatrics.2020.0878](https://doi.org/10.1001/jamapediatrics.2020.0878). [PubMed: [32215598](https://pubmed.ncbi.nlm.nih.gov/32215598/)]. [PubMed Central: [PMC7099530](https://pubmed.ncbi.nlm.nih.gov/PMC7099530/)].
- Yu N, Li W, Kang Q, Xiong Z, Wang S, Lin X, et al. Clinical features and obstetric and neonatal outcomes of pregnant patients with COVID-19 in Wuhan, China: a retrospective, single-centre, descriptive study. *Lancet Infect Dis*. 2020;**20**(5):559-64. doi: [10.1016/S1473-3099\(20\)30176-6](https://doi.org/10.1016/S1473-3099(20)30176-6). [PubMed: [32220284](https://pubmed.ncbi.nlm.nih.gov/32220284/)]. [PubMed Central: [PMC7158904](https://pubmed.ncbi.nlm.nih.gov/PMC7158904/)].
- Udugama B, Kadhiresan P, Kozłowski HN, Malekjahani A, Osborne M, Li VYC, et al. Diagnosing COVID-19: The Disease and Tools for Detection. *ACS Nano*. 2020;**14**(4):3822-35. doi: [10.1021/acsnano.0c02624](https://doi.org/10.1021/acsnano.0c02624). [PubMed: [32223179](https://pubmed.ncbi.nlm.nih.gov/32223179/)]. [PubMed Central: [PMC7144809](https://pubmed.ncbi.nlm.nih.gov/PMC7144809/)].
- Wang L, Shi Y, Xiao T, Fu J, Feng X, Mu D, et al. Chinese expert consensus on the perinatal and neonatal management for the prevention and control of the 2019 novel coronavirus infection (First edition). *Ann Transl Med*. 2020;**8**(3):47. doi: [10.21037/atm.2020.02.20](https://doi.org/10.21037/atm.2020.02.20). [PubMed: [32154287](https://pubmed.ncbi.nlm.nih.gov/32154287/)]. [PubMed Central: [PMC7036629](https://pubmed.ncbi.nlm.nih.gov/PMC7036629/)].
- Li Q, Guan X, Wu P, Wang X, Zhou L, Tong Y, et al. Early Transmission Dynamics in Wuhan, China, of Novel Coronavirus-Infected Pneumonia. *N Engl J Med*. 2020;**382**(13):1199-207. doi: [10.1056/NEJMoa2001316](https://doi.org/10.1056/NEJMoa2001316). [PubMed: [31995857](https://pubmed.ncbi.nlm.nih.gov/31995857/)]. [PubMed Central: [PMC7121484](https://pubmed.ncbi.nlm.nih.gov/PMC7121484/)].
- Janardhanan R. Myocarditis with very high troponins: risk stratification by cardiac magnetic resonance. *J Thorac Dis*. 2016;**8**(10):E1333-6. doi: [10.21037/jtd.2016.10.60](https://doi.org/10.21037/jtd.2016.10.60). [PubMed: [27867620](https://pubmed.ncbi.nlm.nih.gov/27867620/)]. [PubMed Central: [PMC5107455](https://pubmed.ncbi.nlm.nih.gov/PMC5107455/)].
- Assomull RG, Lyne JC, Keenan N, Gulati A, Bunce NH, Davies SW, et al. The role of cardiovascular magnetic resonance in patients presenting with chest pain, raised troponin, and unobstructed coronary arteries. *Eur Heart J*. 2007;**28**(10):1242-9. doi: [10.1093/eurheartj/ehm113](https://doi.org/10.1093/eurheartj/ehm113). [PubMed: [17478458](https://pubmed.ncbi.nlm.nih.gov/17478458/)].
- Wang D, Hu B, Hu C, Zhu F, Liu X, Zhang J, et al. Clinical Characteristics of 138 Hospitalized Patients With 2019 Novel Coronavirus-Infected Pneumonia in Wuhan, China. *JAMA*. 2020. doi: [10.1001/jama.2020.1585](https://doi.org/10.1001/jama.2020.1585). [PubMed: [32031570](https://pubmed.ncbi.nlm.nih.gov/32031570/)]. [PubMed Central: [PMC7042881](https://pubmed.ncbi.nlm.nih.gov/PMC7042881/)].

26. Zeng JH, Liu YX, Yuan J, Wang FX, Wu WB, Li JX, et al. First case of COVID-19 complicated with fulminant myocarditis: a case report and insights. *Infection*. 2020. doi: [10.1007/s15010-020-01424-5](https://doi.org/10.1007/s15010-020-01424-5). [PubMed: [32277408](https://pubmed.ncbi.nlm.nih.gov/32277408/)]. [PubMed Central: [PMC7146072](https://pubmed.ncbi.nlm.nih.gov/PMC7146072/)].
27. Hu H, Ma F, Wei X, Fang Y. Coronavirus fulminant myocarditis saved with glucocorticoid and human immunoglobulin. *Eur Heart J*. 2020. doi: [10.1093/eurheartj/ehaa190](https://doi.org/10.1093/eurheartj/ehaa190). [PubMed: [32176300](https://pubmed.ncbi.nlm.nih.gov/32176300/)]. [PubMed Central: [PMC7184348](https://pubmed.ncbi.nlm.nih.gov/PMC7184348/)].
28. Clerkin KJ, Fried JA, Raikhelkar J, Sayer G, Griffin JM, Masoumi A, et al. COVID-19 and Cardiovascular Disease. *Circulation*. 2020;**141**(20):1648–55. doi: [10.1161/CIRCULATIONAHA.120.046941](https://doi.org/10.1161/CIRCULATIONAHA.120.046941). [PubMed: [32200663](https://pubmed.ncbi.nlm.nih.gov/32200663/)].
29. Guo T, Fan Y, Chen M, Wu X, Zhang L, He T, et al. Cardiovascular Implications of Fatal Outcomes of Patients With Coronavirus Disease 2019 (COVID-19). *JAMA Cardiol*. 2020. doi: [10.1001/jamacardio.2020.1017](https://doi.org/10.1001/jamacardio.2020.1017). [PubMed: [32219356](https://pubmed.ncbi.nlm.nih.gov/32219356/)]. [PubMed Central: [PMC7101506](https://pubmed.ncbi.nlm.nih.gov/PMC7101506/)].
30. Mardani M, Pourkaveh B. A Controversial Debate: Vertical Transmission of COVID-19 in Pregnancy. *Arch Clin Infect Dis*. 2020;**15**(1). e102286. doi: [10.5812/archcid.102286](https://doi.org/10.5812/archcid.102286).